National Comprehensive Cancer Network®

NCCN Clinical Practice Guidelines in Oncology (NCCN Guidelines®)

Dermatofibrosarcoma Protuberans

Version 2.2026 — October 24, 2025

NCCN.org

NCCN recognizes the importance of clinical trials and encourages participation when applicable and available. Trials should be designed to maximize inclusiveness and broad representative enrollment.

Continue

Version 2.2026, 10/24/2025 © 2025 National Comprehensive Cancer Network® (NCCN®), All rights reserved. NCCN Guidelines® and this illustration may not be reproduced in any form without the express written permission of NCCN.

PLEASE NOTE that use of this NCCN Content is governed by the End-User License Agreement, and you MAY NOT distribute this Content or use it with any artificial intelligence model or tool.
Printed by Máximo López Chenlo on 5/4/2026 6:18:17 PM. Copyright © 2026 National Comprehensive Cancer Network, Inc. All Rights Reserved.

NCCN Guidelines Version 2.2026 Dermatofibrosarcoma Protuberans

***Jeremy Bordeaux, MD, MPH/Chair ϖ**
Case Comprehensive Cancer Center/
University Hospitals Seidman Cancer Center
and Cleveland Clinic Taussig Cancer Institute

***Paul Nghiem, MD, PhD/Vice Chair ϖ**
Fred Hutchinson Cancer Center

Sumaira Z. Aasi, MD ϖ
Stanford Cancer Institute

Murad Alam, MD, MBA, MSCI ϖ ¶ ζ
Robert H. Lurie Comprehensive Cancer
Center of Northwestern University

Arya Amini, MD §
City of Hope National Medical Center

Diana Bolotin, MD, PhD ϖ
The UChicago Medicine
Comprehensive Cancer Center

Jennifer Chang, MD ф
UC San Diego Moores Cancer Center

Pei-Ling Chen, MD, PhD ≠
Moffitt Cancer Center

Carlo M. Contreras, MD ¶
The Ohio State University Comprehensive
Cancer Center - James Cancer Hospital
and Solove Research Institute

Jessica M. Donigan, MD ϖ ¶
Huntsman Cancer Institute
at the University of Utah

Daniel Eisen, MD ϖ
UC Davis Comprehensive Cancer Center

Jeffrey M. Farma, MD ¶
Fox Chase Cancer Center

*** Kelly Harms, MD, PhD ϖ**
University of Michigan Rogel Cancer Center

Nicole LeBoeuf, MD, MPH ϖ
Dana-Farber/Brigham and Women's Cancer
Center | Mass General Cancer Center

John Nicholas Lukens, MD §
Abramson Cancer Center
at the University of Pennsylvania

Susan Manber ¥
Publicis Health

Lawrence Mark, MD, PhD ϖ
Indiana University Melvin and Bren Simon
Comprehensive Cancer Center

Stacy McMurray, MD ϖ
Vanderbilt-Ingram Cancer Center

Theresa Medina, MD †
University of Colorado Cancer Center

Kishwer S. Nehal, MD ϖ
Memorial Sloan Kettering Cancer Center

Kelly Olino, MD ¶
Yale Cancer Center/Smilow Cancer Hospital

Gyorgy Paragh, MD, PhD, FAAD ϖ
Roswell Park Comprehensive Cancer Center

Soo Park, MD †
UC San Diego Moores Cancer Center

Tejesh Patel, MD ϖ
The University of Tennessee Health Science Center

Jason Rich, MD ζ
Siteman Cancer Center at Barnes-Jewish Hospital
and Washington University School of Medicine

Ashok R. Shaha, MD ¶
Memorial Sloan Kettering Cancer Center

Bhavina Sharma, MD, MPH ‡
Fred & Pamela Buffett Cancer Center

Olayemi Sokumbi, MD ϖ ≠
Mayo Clinic Comprehensive Cancer Center

Divya Srivastava, MD ϖ
UT Southwestern Simmons Comprehensive Cancer Center

Joel Sunshine, MD, PhD ϖ ≠
Johns Hopkins Kimmel Cancer Center

Valencia Thomas, MD ϖ ≠ ¶
The University of Texas MD Anderson Cancer Center

Puja Venkat, MD §
UCLA Jonsson Comprehensive Cancer Center

Melodi Whitley, MD, PhD ϖ
Duke Cancer Institute

Yaohui Gloria Xu, MD, PhD ϖ Ÿ
University of Wisconsin
Carbone Cancer Center

Siegrid Yu, MD ϖ
UCSF Helen Diller Family Comprehensive Cancer Center

Mehran Yusuf, MD §
O'Neal Comprehensive Cancer Center at UAB

NCCN
Sara Espinosa, PhD
Beth McCullough, RN, BS

ϖ Dermatology
ф Diagnostic/Interventional radiology
‡ Hematology/Hematology oncology
Þ Internal medicine
† Medical oncology
ζ Otolaryngology
≠ Pathology/Dermatopathology
¥ Patient advocacy
§ Radiotherapy/Radiation oncology
Ÿ Reconstructive surgery
¶ Surgery/Surgical oncology
* Discussion Section Writing Committee

NCCN Guidelines Panel Disclosures

Continue

Version 2.2026, 10/24/2025 © 2025 National Comprehensive Cancer Network® (NCCN®), All rights reserved. NCCN Guidelines® and this illustration may not be reproduced in any form without the express written permission of NCCN.

PLEASE NOTE that use of this NCCN Content is governed by the End-User License Agreement, and you MAY NOT distribute this Content or use it with any artificial intelligence model or tool.
Printed by Máximo López Chenlo on 5/4/2026 6:18:17 PM. Copyright © 2026 National Comprehensive Cancer Network, Inc. All Rights Reserved.

NCCN Guidelines Version 2.2026 Dermatofibrosarcoma Protuberans

NCCN Dermatofibrosarcoma Protuberans Panel Members
Summary of the Guidelines Updates

Clinical Presentation and Workup (DFSP-1)
Treatment (DFSP-2)
Follow-up and Therapy for Recurrence/Metastasis (DFSP-3)

Principles of Pathology (DFSP-A)
Principles of Surgery (DFSP-B)
Principles of Radiation Therapy (DFSP-C)

Abbreviations (ABBR-1)

Find an NCCN Member Institution: https://www.nccn.org/home/member-institutions.

NCCN Categories of Evidence and Consensus: All recommendations are category 2A unless otherwise indicated.

See NCCN Categories of Evidence and Consensus.

NCCN Categories of Preference: All recommendations are considered appropriate.

See NCCN Categories of Preference.

The NCCN Guidelines® are a statement of evidence and consensus of the authors regarding their views of currently accepted approaches to treatment. Any clinician seeking to apply or consult the NCCN Guidelines is expected to use independent medical judgment in the context of individual clinical circumstances to determine any patient's care or treatment. The National Comprehensive Cancer Network® (NCCN®) makes no representations or warranties of any kind regarding their content, use or application and disclaims any responsibility for their application or use in any way. The NCCN Guidelines are copyrighted by National Comprehensive Cancer Network®. All rights reserved. The NCCN Guidelines and the illustrations herein may not be reproduced in any form without the express written permission of NCCN. ©2025.

PLEASE NOTE that use of this NCCN Content is governed by the End-User License Agreement, and you MAY NOT distribute this Content or use it with any artificial intelligence model or tool.
Printed by Máximo López Chenlo on 5/4/2026 6:18:17 PM. Copyright © 2026 National Comprehensive Cancer Network, Inc. All Rights Reserved.

Updates in Version 2.2026 of the NCCN Guidelines for Dermatofibrosarcoma Protuberans from Version 1.2026 include:

MS-1
- The discussion section has been updated to reflect changes in the algorithm.

Updates in Version 1.2026 of the NCCN Guidelines for Dermatofibrosarcoma Protuberans from Version 1.2025 include:

DFSP-1
- Preliminary Workup, second bullet, sub-bullet removed: Debulking specimens from all excisions should be examined to identify fibrosarcomatous transformation of dermatofibrosarcoma protuberans (FS-DFSP).
- Footnote removed: If areas of transformation to fibrosarcoma or other sarcoma subtypes are identified, multidisciplinary consultation for consideration of further treatment and surveillance is recommended. FS-DFSP is associated with a higher metastasis risk. The patient should be referred to a center with expertise in management of soft tissue sarcomas. See NCCN Guidelines for Soft Tissue Sarcoma for multimodal therapy and surveillance considerations including CT of draining nodal basin and chest.

DFSP-2
- Treatment, new bullet added: Debulking specimens from all excisions should be examined to identify fibrosarcomatous transformation of dermatofibrosarcoma protuberans (FS-DFSP).
- Adjuvant Treatment bottom pathway revised: ~~Multidisciplinary consultation for consideration of~~ *Consider* radiation therapy (RT) ~~or other therapy~~ *if margins are deemed narrow by treating physician and further resection would not be feasible upon recurrence.*
- Follow-Up header and bullets in that column removed:
  - Physical exam with focus on primary site every 6–12 months.
  - Patient education about regular self-exam.
  - Consider MRI surveillance for deeply invasive disease or other concerns for recurrence.
- Last column revised: ~~Therapy for Recurrence/ Metastasis~~ *Follow-up* (DFSP-3).
- Footnotes revised:
  - Footnote c: . . .The patient should be referred to a center with expertise in management of soft tissue sarcomas. See NCCN Guidelines for Soft Tissue Sarcoma for multimodal therapy and surveillance considerations including CT of ~~draining nodal basin and~~ chest.
  - Footnote e: . . .Wide undermining is discouraged prior to confirmation of clear margins due to the difficulty of interpreting subsequent re-excised margins, and the risk of concealing residual tumor below mobilized tissue. See Principles of Surgery (DFSP-B). Curtis KK, et al. J Natl Compr Canc Netw *2024;22:e247036*. (Also page DFSP-3)
- Footnote removed: When Mohs or other forms of PDEMA are not utilized and margins are negative, RT is not recommended. When Mohs or other forms of PDEMA are not utilized, consider RT if margins are considered narrow by the treating physicians. RT if not given previously and further resection is not feasible.

Continued

Version 2.2026, 10/24/2025 © 2025 National Comprehensive Cancer Network® (NCCN®), All rights reserved. NCCN Guidelines® and this illustration may not be reproduced in any form without the express written permission of NCCN.

PLEASE NOTE that use of this NCCN Content is governed by the End-User License Agreement, and you MAY NOT distribute this Content or use it with any artificial intelligence model or tool.
Printed by Máximo López Chenlo on 5/4/2026 6:18:17 PM. Copyright © 2026 National Comprehensive Cancer Network, Inc. All Rights Reserved.

Updates in Version 1.2026 of the NCCN Guidelines for Dermatofibrosarcoma Protuberans from Version 1.2025 include:

DFSP-3
- New header added: Follow-Up.
  - New bullets added:
    - ◊ Physical exam with focus on primary site every 6–12 months.
    - ◊ Patient education about regular self-exam.
    - ◊ Consider MRI surveillance when clinical exam is insufficient to assess local recurrence.
- Footnotes revised:
  - Footnote h: When Mohs or other forms of PDEMA are utilized and margins are negative, RT is not recommended. When Mohs or other forms of PDEMA are not utilized, consider RT if margins are considered narrow by the treating physicians *and further resection would not be feasible upon recurrence.* ~~RT if not given previously and further resection is not feasible.~~
  - Footnote i: Confirm ~~tumor mutation with~~ *COL1A1::PDGFB translocation by* fluorescence in situ hybridization (FISH) ~~for the translocation of PDGRF~~. Navarrete-Dechent C, et al. JAMA Dermatol 2019;155:361-369.

DFSP-A
- Fifth bullet revised: For equivocal lesions, consider fluorescence in situ hybridization (FISH), polymerase chain reaction (PCR), or conventional cytogenetics to detect t(17;22)(q22;q13), which is a hallmark of DFSP. Fusion of ~~the collagen type I alpha 1 gene (~~*COL1A1*~~)~~ at 17q22, with ~~the platelet-derived growth factor Beta gene (~~*PDGFB*β~~)~~ at 22q13, form the oncogenic chimeric fusion gene *COL1A1::PDGFB*β.

DFSP-C
- General Treatment Information, Adjuvant RT, Negative Margins, second sub-bullet revised: When Mohs or other forms of PDEMA are not utilized, consider RT if margins are considered narrow by the treating physician *and further resection would not be feasible upon recurrence*~~, RT not given previously, and further resection is not feasible~~.

Version 2.2026, 10/24/2025 © 2025 National Comprehensive Cancer Network® (NCCN®), All rights reserved. NCCN Guidelines® and this illustration may not be reproduced in any form without the express written permission of NCCN.

PLEASE NOTE that use of this NCCN Content is governed by the End-User License Agreement, and you MAY NOT distribute this Content or use it with any artificial intelligence model or tool.
Printed by Máximo López Chenlo on 5/4/2026 6:18:17 PM. Copyright © 2026 National Comprehensive Cancer Network, Inc. All Rights Reserved.

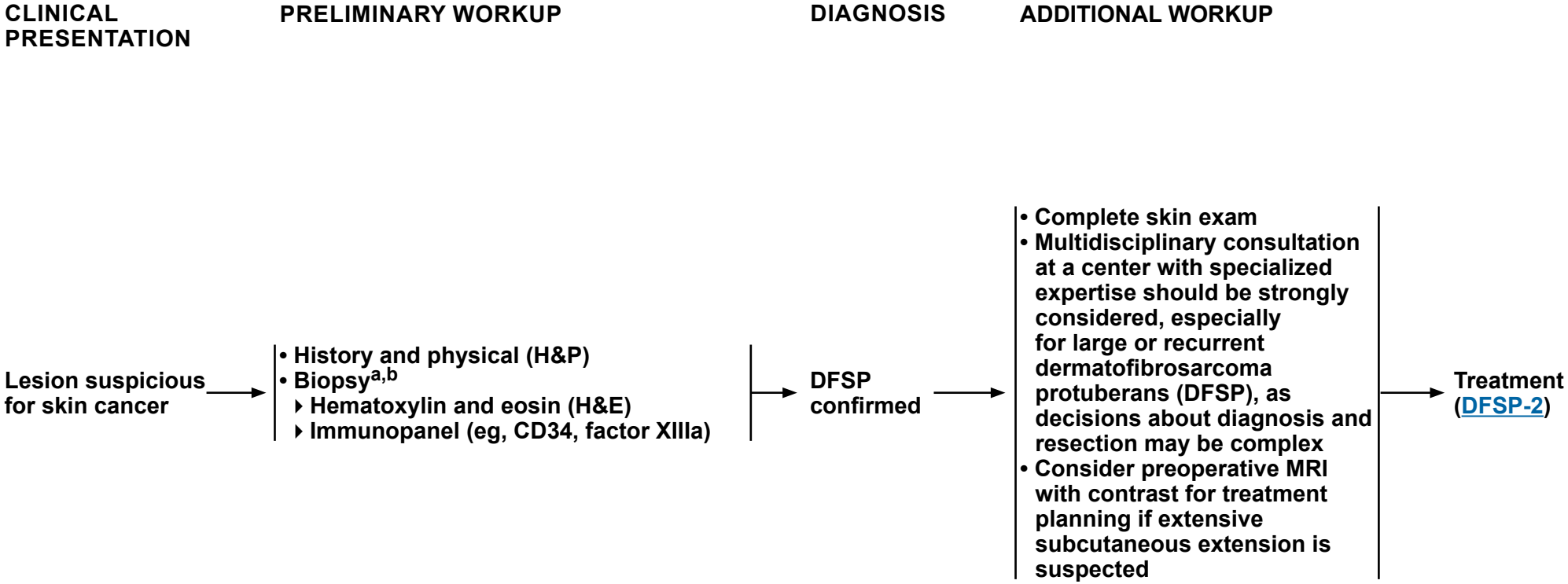

[a] This tumor is frequently misdiagnosed due to inadequate tissue sampling/superficial biopsy. Punch, incisional, or core biopsy, preferably including the deeper subcutaneous layer, is strongly recommended for sufficient tissue sampling and accurate pathologic assessment. If biopsy is indeterminate or clinical suspicion remains, rebiopsy is recommended. Wide undermining is discouraged due to the difficulty of interpreting subsequent re-excisions pathologically.
[b] Principles of Pathology (DFSP-A).

Note: All recommendations are category 2A unless otherwise indicated.

Version 2.2026, 10/24/2025 © 2025 National Comprehensive Cancer Network® (NCCN®), All rights reserved. NCCN Guidelines® and this illustration may not be reproduced in any form without the express written permission of NCCN.

PLEASE NOTE that use of this NCCN Content is governed by the End-User License Agreement, and you MAY NOT distribute this Content or use it with any artificial intelligence model or tool.
Printed by Máximo López Chenlo on 5/4/2026 6:18:17 PM. Copyright © 2026 National Comprehensive Cancer Network, Inc. All Rights Reserved.

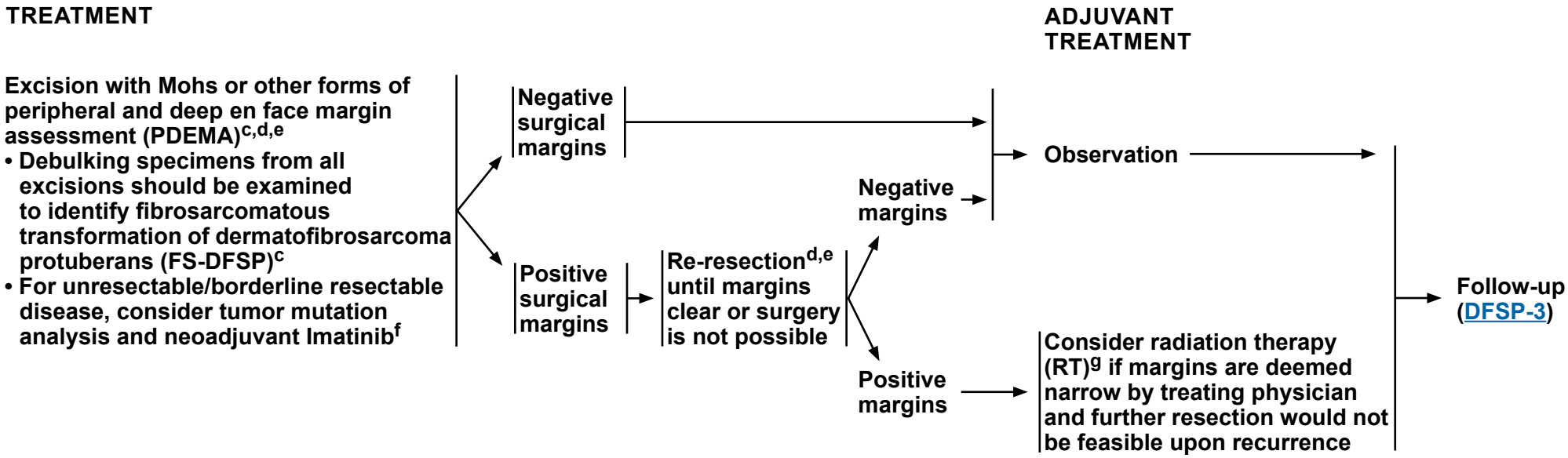

[c] If areas of transformation to fibrosarcoma or other sarcoma subtypes are identified, multidisciplinary consultation for consideration of further treatment and surveillance is recommended. FS-DFSP is associated with a higher metastasis risk. The patient should be referred to a center with expertise in management of soft tissue sarcomas. See NCCN Guidelines for Soft Tissue Sarcoma for multimodal therapy and surveillance considerations including CT of chest.

[d] The most commonly used form of PDEMA is Mohs. See NCCN Guidelines for Squamous Cell Skin Cancer - Principles of PDEMA Technique. When anatomic structures at the deep margin (eg, major vessels, nerves, bone) preclude complete histologic evaluation of the marginal surface, Mohs or other forms of PDEMA should be used to evaluate as much of the marginal surface as feasible. Treatment considerations for non-visualized areas may be the subject of multidisciplinary discussion.

[e] If PDEMA is unavailable, consider wide excision. Wide undermining is discouraged prior to confirmation of clear margins due to the difficulty of interpreting subsequent re-excised margins, and the risk of concealing residual tumor below mobilized tissue. See Principles of Surgery (DFSP-B). Curtis KK, et al. J Natl Compr Canc Netw 2024;22:e247036.

[f] Consider neoadjuvant Imatinib for patients in whom resection with negative margins may result in unacceptable functional or cosmetic outcomes. Ugurel S, et al. Clin Cancer Res 2014;20:499-510.

[g] Principles of Radiation Therapy (DFSP-C).

Note: All recommendations are category 2A unless otherwise indicated.

Version 2.2026, 10/24/2025 © 2025 National Comprehensive Cancer Network® (NCCN®), All rights reserved. NCCN Guidelines® and this illustration may not be reproduced in any form without the express written permission of NCCN.

PLEASE NOTE that use of this NCCN Content is governed by the End-User License Agreement, and you MAY NOT distribute this Content or use it with any artificial intelligence model or tool.
Printed by Máximo López Chenlo on 5/4/2026 6:18:17 PM. Copyright © 2026 National Comprehensive Cancer Network, Inc. All Rights Reserved.

FOLLOW-UP

- Physical exam with focus on primary site every 6–12 months
- Patient education about regular self-exam
- Consider MRI surveillance when clinical exam is insufficient to assess local recurrence

Recurrence →

Re-resection if feasible (preferred)[d,e]
or
RT[g,h] if not given previously and resection is not feasible
or
Consider Imatinib[i] in cases where disease is unresectable, or unacceptable functional or cosmetic outcomes will occur with resection

Metastasis → **Multidisciplinary consultation[j]**

THERAPY FOR RECURRENCE/METASTASIS

[d] The most commonly used form of PDEMA is Mohs. See NCCN Guidelines for Squamous Cell Skin Cancer - Principles of PDEMA Technique. When anatomic structures at the deep margin (eg, major vessels, nerves, bone) preclude complete histologic evaluation of the marginal surface, Mohs or other forms of PDEMA should be used to evaluate as much of the marginal surface as feasible. Treatment considerations for non-visualized areas may be the subject of multidisciplinary discussion.
[e] If PDEMA is unavailable, consider wide excision. Wide undermining is discouraged prior to confirmation of clear margins due to the difficulty of interpreting subsequent re-excised margins, and the risk of concealing residual tumor below mobilized tissue. See Principles of Surgery (DFSP-B). Curtis KK, et al. J Natl Compr Canc Netw 2024;22:e247036.
[g] Principles of Radiation Therapy (DFSP-C).
[h] When Mohs or other forms of PDEMA are utilized and margins are negative, RT is not recommended. When Mohs or other forms of PDEMA are not utilized, consider RT if margins are considered narrow by the treating physicians and further resection would not be feasible upon recurrence.
[i] Confirm *COL1A1::PDGFB* translocation by fluorescence in situ hybridization (FISH). Navarrete-Dechent C, et al. JAMA Dermatol 2019;155:361-369.
[j] NCCN Guidelines for Soft Tissue Sarcoma (Synchronous STAGE IV [EXTSARC-5]).

Note: All recommendations are category 2A unless otherwise indicated.

Version 2.2026, 10/24/2025 © 2025 National Comprehensive Cancer Network® (NCCN®), All rights reserved. NCCN Guidelines® and this illustration may not be reproduced in any form without the express written permission of NCCN.

PLEASE NOTE that use of this NCCN Content is governed by the End-User License Agreement, and you MAY NOT distribute this Content or use it with any artificial intelligence model or tool.
Printed by Máximo López Chenlo on 5/4/2026 6:18:17 PM. Copyright © 2026 National Comprehensive Cancer Network, Inc. All Rights Reserved.

PRINCIPLES OF PATHOLOGY[a]

- **Evaluation by a qualified physician with specific expertise in sarcoma/soft tissue pathology or dermatopathology is preferred (if available).**
- **The spindled cells arranged in a storiform or fascicular pattern are typically bland with minimal cytologic atypia.**
- **Immunohistochemistry (IHC) for CD34 is mostly positive, and factor XIIIa negative.**
- **FS-DFSP[b] is characterized by transition from storiform to a herringbone pattern, with a higher degree of cellularity, cytologic atypia, mitotic activity (>5/10 high-power fields [HPFs]), and frequent loss of CD34 immunostaining. When CD34 is negative, other markers such as S100 should also be negative to rule out other spindle cell tumors.**
- **For equivocal lesions, consider fluorescence in situ hybridization (FISH), polymerase chain reaction (PCR), or conventional cytogenetics to detect t(17;22)(q22;q13), which is a hallmark of DFSP. Fusion of *COL1A1* at 17q22, with *PDGFB* at 22q13, form the oncogenic chimeric fusion gene *COL1A1::PDGFB*.**
- **Margin control during excision (see Principles of Surgery [DFSP-B]) may occasionally be aided by H&E sections supplemented by CD34 IHC.**

[a] Currently, no American Joint Committee on Cancer (AJCC) or College of American Pathologists (CAP) synoptic reporting is defined.
[b] If areas of transformation to fibrosarcoma or other sarcoma subtypes are identified, multidisciplinary consultation for consideration of further treatment and surveillance is recommended. FS-DFSP is associated with a higher metastasis risk. The patient should be referred to a center with expertise in management of soft tissue sarcomas. See NCCN Guidelines for Soft Tissue Sarcoma for multimodal therapy and surveillance considerations including CT of draining nodal basin and chest.

Note: All recommendations are category 2A unless otherwise indicated.

Version 2.2026, 10/24/2025 © 2025 National Comprehensive Cancer Network® (NCCN®), All rights reserved. NCCN Guidelines® and this illustration may not be reproduced in any form without the express written permission of NCCN.

PLEASE NOTE that use of this NCCN Content is governed by the End-User License Agreement, and you MAY NOT distribute this Content or use it with any artificial intelligence model or tool.
Printed by Máximo López Chenlo on 5/4/2026 6:18:17 PM. Copyright © 2026 National Comprehensive Cancer Network, Inc. All Rights Reserved.

PRINCIPLES OF SURGERY

Goal:

- **Every effort should be made to achieve clear surgical margins. Complete histologic surgical margin examination to include the entire excised peripheral and deep margin is recommended, whenever possible. Tumor characteristics include long, irregular, subclinical extensions. Debulking specimens from all excisions should be examined to identify FS-DFSP since this is associated with metastatic potential.**

Surgical Approach: Mohs or Other Forms of PDEMA

- **NCCN Guidelines for Squamous Cell Skin Cancer - Principles of PDEMA Technique**
- **If Mohs or other forms of PDEMA are unavailable, consider wide excision.[1]**
  - **Reconstruction should be delayed until clear margins have been verified to avoid the risk of translocating the tumor within the resection bed, thus making further margin assessments inaccurate.**

[1] Farma JM, Ammori JB, Zager JS, et al. Dermatofibrosarcoma protuberans: how wide should we resect? Ann Surg Oncol 2010;17:2112-2118.

Note: All recommendations are category 2A unless otherwise indicated.

Version 2.2026, 10/24/2025 © 2025 National Comprehensive Cancer Network® (NCCN®), All rights reserved. NCCN Guidelines® and this illustration may not be reproduced in any form without the express written permission of NCCN.

PLEASE NOTE that use of this NCCN Content is governed by the End-User License Agreement, and you MAY NOT distribute this Content or use it with any artificial intelligence model or tool.
Printed by Máximo López Chenlo on 5/4/2026 6:18:17 PM. Copyright © 2026 National Comprehensive Cancer Network, Inc. All Rights Reserved.

PRINCIPLES OF RADIATION THERAPY

General Treatment Information

- **Adjuvant RT:**
  - **Positive Margins/Gross Disease**
    - **50–60 Gy for indeterminate or positive margins, and up to 66 Gy for positive margins or gross tumor (2-Gy fractions per day).**
    - **Fields to extend widely beyond surgical margins (eg, 3–5 cm) when clinically feasible.**
  - **Negative Margins**
    - **When Mohs or other forms of PDEMA are utilized and margins are negative, RT is not recommended.**
    - **When Mohs or other forms of PDEMA are not utilized, consider RT if margins are considered narrow by the treating physician and further resection would not be feasible upon recurrence.**
- **Recurrence/Metastasis:**
  - **RT if not given previously and further resection is not feasible; 50–60 Gy for indeterminate or positive margins, and up to 66 Gy for positive margins or gross tumor (2-Gy fractions per day).**
  - **Fields to extend widely beyond surgical margins (eg, 3–5 cm) when clinically feasible.**

Note: All recommendations are category 2A unless otherwise indicated.

Version 2.2026, 10/24/2025 © 2025 National Comprehensive Cancer Network® (NCCN®), All rights reserved. NCCN Guidelines® and this illustration may not be reproduced in any form without the express written permission of NCCN.

PLEASE NOTE that use of this NCCN Content is governed by the End-User License Agreement, and you MAY NOT distribute this Content or use it with any artificial intelligence model or tool.
Printed by Máximo López Chenlo on 5/4/2026 6:18:17 PM. Copyright © 2026 National Comprehensive Cancer Network, Inc. All Rights Reserved.

ABBREVIATIONS

CAP	**College of American Pathologists**
DFSP	**dermatofibrosarcoma protuberans**
FISH	**fluorescence in situ hybridization**
FS-DFSP	**fibrosarcomatous transformation of DFSP**
H&E	**hematoxylin and eosin**
H&P	**history and physical**
HPF	**high-power field**
IHC	**immunohistochemistry**
PCR	**polymerase chain reaction**
PDEMA	**peripheral and deep en face margin assessment**

Version 2.2026, 10/24/2025 © 2025 National Comprehensive Cancer Network® (NCCN®), All rights reserved. NCCN Guidelines® and this illustration may not be reproduced in any form without the express written permission of NCCN.

PLEASE NOTE that use of this NCCN Content is governed by the End-User License Agreement, and you MAY NOT distribute this Content or use it with any artificial intelligence model or tool.
Printed by Máximo López Chenlo on 5/4/2026 6:18:17 PM. Copyright © 2026 National Comprehensive Cancer Network, Inc. All Rights Reserved.

NCCN Categories of Evidence and Consensus	
Category 1	Based upon high-level evidence (≥1 randomized phase 3 trials or high-quality, robust meta-analyses), there is uniform NCCN consensus (≥85% support of the Panel) that the intervention is appropriate.
Category 2A	Based upon lower-level evidence, there is uniform NCCN consensus (≥85% support of the Panel) that the intervention is appropriate.
Category 2B	Based upon lower-level evidence, there is NCCN consensus (≥50%, but <85% support of the Panel) that the intervention is appropriate.
Category 3	Based upon any level of evidence, there is major NCCN disagreement that the intervention is appropriate.

All recommendations are category 2A unless otherwise indicated.

NCCN Categories of Preference	
Preferred	Interventions that are based on superior efficacy, safety, and evidence; and, when appropriate, affordability.
Other recommended	Other interventions that may be somewhat less efficacious, more toxic, or based on less mature data; or significantly less affordable for similar outcomes.
Useful in certain circumstances	Other interventions that may be used for selected patient populations (defined with recommendation).

All recommendations are considered appropriate.

Version 2.2026, 10/24/2025 © 2025 National Comprehensive Cancer Network® (NCCN®), All rights reserved. NCCN Guidelines® and this illustration may not be reproduced in any form without the express written permission of NCCN.

PLEASE NOTE that use of this NCCN Content is governed by the End-User License Agreement, and you MAY NOT distribute this Content or use it with any artificial intelligence model or tool.
Printed by Máximo López Chenlo on 5/4/2026 6:18:17 PM. Copyright © 2026 National Comprehensive Cancer Network, Inc. All Rights Reserved.

Discussion

This discussion corresponds to the NCCN Guidelines for Dermatofibrosarcoma Protuberans. Last updated: October 24, 2025

Table of Contents

Overview MS-2
Guidelines Update Methodology MS-2
Literature Search Criteria and Guidelines Update Methodology MS-2
Sensitive/Inclusive Language MS-2
Evaluation MS-3
Treatment MS-3
Follow-up MS-5
References MS-6

Version 2.2026 © 2025 National Comprehensive Cancer Network© (NCCN©), All rights reserved. NCCN Guidelines® and this illustration may not be reproduced in any form without the express written permission of NCCN.

PLEASE NOTE that use of this NCCN Content is governed by the End-User License Agreement, and you MAY NOT distribute this Content or use it with any artificial intelligence model or tool.
Printed by Máximo López Chenlo on 5/4/2026 6:18:17 PM. Copyright © 2026 National Comprehensive Cancer Network, Inc. All Rights Reserved.

Overview

Dermatofibrosarcoma protuberans (DFSP) is an uncommon, low-grade sarcoma of fibroblast origin with an incidence rate of 4.1 to 4.5 cases per million persons per year in the United States.[1-4] A predilection for occurring in African Americans has been reported in one study.[3] They are often clinically misdiagnosed, leading to prolonged time to diagnosis. However, DFSP rarely metastasizes.[5] When metastasis occurs, it is typically in the lung, bone, or regional lymph nodes. Three-dimensional reconstruction of DFSP[6] has revealed tumors with highly irregular shapes and frequent finger-like extensions.[7] As a result, incomplete removal and subsequent recurrence are common without attention to full assessment of the peripheral and deep margin. The local recurrence rate for wide local excision (WLE) of DFSP in studies ranges from 10% to 60%, whereas the rate of development of regional or distant metastatic disease is only 1% and 4-7.4%, respectively.[8,9]

Guidelines Update Methodology

The complete details of the Development and Update of the NCCN Guidelines are available at www.NCCN.org.

Literature Search Criteria and Guidelines Update Methodology

Prior to the update of this version of the NCCN Clinical Practice Guidelines in Oncology (NCCN Guidelines®) for Dermatofibrosarcoma Protuberans, an electronic search of the PubMed database was performed to obtain key literature using the following search term: dermatofibrosarcoma protuberans. The PubMed database was chosen as it remains the most widely used resource for medical literature and indexes peer-reviewed biomedical literature.[10]

The search results were narrowed by selecting studies in humans published in English. Results were confined to the following article types: Clinical Trial; Guideline; Meta-Analysis; Practice Guideline; Randomized Controlled Trial; Systematic Reviews; and Validation Studies.

The data from key PubMed articles as well as articles from additional sources deemed as relevant to these guidelines as discussed by the Panel during the Guidelines update have been included in this version of the Discussion section. Recommendations for which high-level evidence is lacking are based on the Panel's review of lower-level evidence and expert opinion.

Sensitive/Inclusive Language

NCCN Guidelines strive to use language that advances the goals of equity, inclusion, and representation.[11] NCCN Guidelines endeavor to use language that is person-first; not stigmatizing; anti-racist, anti-classist, anti-misogynist, anti-ageist, anti-ableist, and anti-weight biased; and inclusive of individuals of all sexual orientations and gender identities. NCCN Guidelines incorporate non-gendered language, instead focusing on organ-specific recommendations. This language is both more accurate and more inclusive and can help fully address the needs of individuals of all sexual orientations and gender identities. NCCN Guidelines will continue to use the terms men, women, female, and male when citing statistics, recommendations, or data from organizations or sources that do not use inclusive terms. Most studies do not report how sex and gender data are collected and use these terms interchangeably or inconsistently. If sources do not differentiate gender from sex assigned at birth or organs present, the information is presumed to predominantly represent cisgender individuals. NCCN encourages researchers to collect more specific data in future studies and organizations to use more inclusive and accurate language in their future analyses.

Version 2.2026 © 2025 National Comprehensive Cancer Network© (NCCN©), All rights reserved. NCCN Guidelines® and this illustration may not be reproduced in any form without the express written permission of NCCN.

PLEASE NOTE that use of this NCCN Content is governed by the End-User License Agreement, and you MAY NOT distribute this Content or use it with any artificial intelligence model or tool.
Printed by Máximo López Chenlo on 5/4/2026 6:18:17 PM. Copyright © 2026 National Comprehensive Cancer Network, Inc. All Rights Reserved.

Evaluation

Preliminary workup for DFSP consists of history and physical (H&P) examination, and biopsy. It should be noted that this tumor is frequently misdiagnosed due to inadequate tissue sampling resulting from shallow biopsy. As the superficial aspect of a DFSP may not be distinct from benign lesions, a punch or incisional biopsy that samples the subcutaneous layer is strongly recommended. If a biopsy is indeterminate or clinical suspicion remains, rebiopsy is recommended. Histologically, DFSP typically presents as a storiform or fascicular proliferation of bland spindled cells that extends from the dermis into the subcutis.[12,13] Virtually all cases are immunohistologically CD34-positive and factor XIIIa-negative with rare exceptions.[14,15] Currently, no synoptic reporting is recommended.

In most cases, examination of hematoxylin and eosin-stained specimens by light microscopy results in an unequivocal diagnosis. However, differentiation of DFSP from dermatofibroma can be difficult at times. Staining with CD34,[15,16] factor XIIIa,[14,17] and other immunomarkers such as stromelysins 3, nestin, apolipoprotein D, and cathepsin K,[18-21] might be useful in such instances. The NCCN Panel recommends that appropriate and confirmatory immunostaining be performed in all cases of suspected DFSP.

After DFSP confirmation, additional workup may include a complete skin examination as well as consideration of preoperative MRI with contrast for treatment planning if there is suspicion of extensive subcutaneous extension. As decisions about diagnosis and resection may be complex, multidisciplinary consultation at a center with specialized expertise should be strongly considered, especially for large or recurrent DFSP as it may optimize clinical and reconstructive outcomes.[22,23]

Treatment

Initial treatment of DFSP is surgical. Because of its proclivity for irregular and frequently deep subclinical extensions, every effort should be made to remove this tumor in its entirety at the time of initial therapy. Excision with Mohs micrographic surgery (Mohs) or other forms of peripheral and deep en face margin assessment (PDEMA) is recommended over WLE. En face sectioning is preferred to prevent missing small foci of tumor. The most commonly used form of PDEMA is Mohs (See NCCN Guidelines for Squamous Cell Skin Cancer – Principles of PDEMA Technique, available at www.NCCN.org).[24] When anatomic structures at the deep margin (eg, major vessels, nerves, bone) preclude complete histologic evaluation of the marginal surface via Mohs or other forms of PDEMA, these surgical techniques should be used to evaluate as much of the marginal surface as feasible. A combination of PDEMA and WLE for the deep margin has been reported in the literature.[23] Treatment considerations for non-visualized areas may be the subject of multidisciplinary discussion. If PDEMA is unavailable, WLE can be considered. Wide undermining is discouraged prior to confirmation of clear margins due to the difficulty of interpreting subsequent re-excised margins, and the risk of concealing residual tumor below mobilized tissue.

It is unclear whether the histologic features of a high mitotic rate or evidence of fibrosarcomatous (FS)-DFSP change have prognostic significance in DFSP.[25,26] Studies in the biomedical literature both support[27-35] the connection between FS-DFSP and an increased risk of local recurrence, lower time to recurrence, and increased risk of metastasis, and refute[36,37] this notion. A systematic review of 225 patients with FS-DFSP and 1422 with DFSP reported risks of local recurrence (29.8% vs. 13.7%), metastasis (14.4% vs. 1.1%), and death (14.7% vs. 0.8%) from the disease to be significantly higher in FS-DFSP.[38] Overall, FS-DFSP is associated with a metastatic risk range of

Version 2.2026 © 2025 National Comprehensive Cancer Network© (NCCN©), All rights reserved. NCCN Guidelines® and this illustration may not be reproduced in any form without the express written permission of NCCN.

PLEASE NOTE that use of this NCCN Content is governed by the End-User License Agreement, and you MAY NOT distribute this Content or use it with any artificial intelligence model or tool.
Printed by Máximo López Chenlo on 5/4/2026 6:18:17 PM. Copyright © 2026 National Comprehensive Cancer Network, Inc. All Rights Reserved.

10% to 23.5%.[26,29,39] The NCCN Panel recommends that the debulking specimens from all excisions should be examined to identify FS transformation of DFSP. If FS transformation or other sarcoma subtypes are found, multidisciplinary consultation for consideration of further treatment and surveillance is recommended. Clinicians should consult the NCCN Guidelines for Soft Tissue Sarcoma (available at www.NCCN.org) for multimodal therapy and surveillance considerations including chest CT.

Additionally, tumor mutation analysis and neoadjuvant imatinib can be considered options for unresectable or borderline resectable disease. Consider neoadjuvant imatinib for patients in whom DFSP resection with negative margins may result in unacceptable functional or cosmetic outcomes.[40] The NCCN Panel recommends that if a negative margin is achieved, no adjuvant treatment is necessary. When Mohs or other forms of PDEMA are used, radiation therapy (RT) is not recommended.

If initial surgery yields positive margins, re-resection is recommended whenever possible, with the goal of achieving clear margins. Mohs or modified Mohs surgery, and traditional WLE with wider margins, which has been associated with higher tumor clearance and lower rates of recurrence,[41-43] are all methods to achieve complete histologic assessment. Studies examining outcomes of both Mohs and WLE have consistently reported lower recurrence rates for the former (0%–6.6% vs. 1.7%–30.8%).[44-53] A large retrospective series of 204 patients with DFSP showed a very low local recurrence rate (1%) using WLE with total peripheral margin pathologic evaluation, underscoring the importance of meticulous pathologic margin evaluation with any surgical technique.[54] This notion was also supported by more studies.[55,56] It is recommended that any reconstruction involving extensive undermining be avoided. Tissue rearrangement, if necessary, should be delayed until negative histologic margins are verified to prevent displacing a potentially positive margin or hampering interpretation of re-excisions. If there is concern that the surgical margins are not clear when Mohs or PDEMA is not available, split-thickness skin grafting should be considered to monitor for recurrence.

While radiation has occasionally been used as a primary therapeutic modality for DFSP,[57-59] it is most beneficial as adjuvant therapy after surgery.[57-64] In a single-institution retrospective review of 53 patients with DFSP treated with surgery and preoperative or postoperative RT, local control was 93% and actuarial overall survival was 98% at 10 years.[37] Another small patient series reported that 86% of patients with DFSP who were treated with postoperative RT remained disease-free at a median follow-up of 10.5 years.[63] In a systematic review and meta-analysis of adjuvant RT for DFSP after WLE, the overall recurrence rate was reported to be 11.74%. Patients with positive/close margins had a recurrence rate of 14.23% whereas those with negative margins had no recurrence.[65] The NCCN Panel recommends that if margins are positive after re-resection, RT can be considered as an adjuvant treatment if the treating physician deems the margins to be narrow and further resection would not be feasible upon recurrence.

DFSP can be treated by targeted platelet-derived growth factor receptor (PDGFRs). DFSP is characterized by a translocation between chromosomes 17 and 22 [t(17;22)(q22;q13)] resulting in the overexpression of *PDGFB*.[66-68] These findings suggest that targeting PDGFRs may be an effective treatment for DFSP. In published results, imatinib mesylate, a protein tyrosine kinase inhibitor, has shown clinical activity against DFSP,[40,69-73] which has led to its approval by the U.S. Food and Drug Administration (FDA) for the treatment of unresectable, recurrent, and/or metastatic DFSP in adult patients. It is still unclear whether or not and the extent to which the *COL1A1::PDGFB* fusion gene dictates imatinib response.[70] In a systematic review that included

Version 2.2026 © 2025 National Comprehensive Cancer Network© (NCCN©), All rights reserved. NCCN Guidelines® and this illustration may not be reproduced in any form without the express written permission of NCCN.

PLEASE NOTE that use of this NCCN Content is governed by the End-User License Agreement, and you MAY NOT distribute this Content or use it with any artificial intelligence model or tool.
Printed by Máximo López Chenlo on 5/4/2026 6:18:17 PM. Copyright © 2026 National Comprehensive Cancer Network, Inc. All Rights Reserved.

patients receiving imatinib as monotherapy, adjuvant, or neoadjuvant therapy, complete response, partial response, stable disease, and progressive disease were reported in 5.2%, 55.2%, 27.6%, and 9.2% of patients, respectively.[70] In the neoadjuvant setting, complete response, partial response, stable disease, and progressive disease rates were reported to be 7.1%, 50%, 35.7%, and 7.1%, respectively.[40]

Follow-up

Given the historically high local recurrence rates for DFSP, ongoing clinical follow-up with focus on the primary site every 6 to 12 months is indicated, with re-biopsy of any suspicious regions. Although metastatic disease is rare, a guided H&P and patient education about regular self-examination are recommended. Consider MRI surveillance for deeply invasive disease or other concerns related to recurrence.

Recurrent tumors should be resected whenever possible. Adjuvant RT may be considered after surgery. For patients who are not surgical candidates, RT alone is an option if not given previously. Imatinib mesylate should be considered in cases where the disease is unresectable following multiple resections, or if unacceptable functional or cosmetic outcomes will occur with further resection. The NCCN Panel recommends that the *COL1A1::PDGFB* translocation be confirmed by fluorescence in-situ hybridization (FISH).[70]

In the rare event of metastatic disease, multidisciplinary consultation is recommended to coordinate treatment (See NCCN Guidelines for Soft Tissue Sarcoma, available at www.NCCN.org).

Version 2.2026 © 2025 National Comprehensive Cancer Network© (NCCN©), All rights reserved. NCCN Guidelines® and this illustration may not be reproduced in any form without the express written permission of NCCN.

PLEASE NOTE that use of this NCCN Content is governed by the End-User License Agreement, and you MAY NOT distribute this Content or use it with any artificial intelligence model or tool.
Printed by Máximo López Chenlo on 5/4/2026 6:18:17 PM. Copyright © 2026 National Comprehensive Cancer Network, Inc. All Rights Reserved.

References

1. Criscione VD, Weinstock MA. Descriptive epidemiology of dermatofibrosarcoma protuberans in the United States, 1973 to 2002. J Am Acad Dermatol 2007;56:968–973. Available at: https://www.ncbi.nlm.nih.gov/pubmed/17141362.

2. Rouhani P, Fletcher CD, Devesa SS, Toro JR. Cutaneous soft tissue sarcoma incidence patterns in the U.S. : an analysis of 12,114 cases. Cancer 2008;113:616–627. Available at: https://www.ncbi.nlm.nih.gov/pubmed/18618615.

3. Kreicher KL, Kurlander DE, Gittleman HR, et al. Incidence and Survival of Primary Dermatofibrosarcoma Protuberans in the United States. Dermatol Surg 2016;42 Suppl 1:S24–31. Available at: https://www.ncbi.nlm.nih.gov/pubmed/26730971.

4. Criscito MC, Martires KJ, Stein JA. Prognostic Factors, Treatment, and Survival in Dermatofibrosarcoma Protuberans. JAMA Dermatol 2016;152:1365–1371. Available at: https://www.ncbi.nlm.nih.gov/pubmed/27262160.

5. Martin L, Piette F, Blanc P, et al. Clinical variants of the preprotuberant stage of dermatofibrosarcoma protuberans. Br J Dermatol 2005;153:932–936. Available at: https://www.ncbi.nlm.nih.gov/pubmed/16225602.

6. Haycox CL, Odland PB, Olbricht SM, Casey B. Dermatofibrosarcoma protuberans (DFSP): growth characteristics based on tumor modeling and a review of cases treated with Mohs micrographic surgery. Ann Plast Surg 1997;38:246–251. Available at: https://www.ncbi.nlm.nih.gov/pubmed/9088462.

7. Ratner D, Thomas CO, Johnson TM, et al. Mohs micrographic surgery for the treatment of dermatofibrosarcoma protuberans. Results of a multiinstitutional series with an analysis of the extent of microscopic spread. J Am Acad Dermatol 1997;37:600–613. Available at: https://www.ncbi.nlm.nih.gov/pubmed/9344201.

8. Hayakawa K, Matsumoto S, Ae K, et al. Risk factors for distant metastasis of dermatofibrosarcoma protuberans. J Orthop Traumatol 2016;17:261–266. Available at: https://www.ncbi.nlm.nih.gov/pubmed/27289468.

9. Vidimos AT, Helm TN, Papay FA. Dermatofibrosarcoma protuberans. In: Cutaneous Oncology: Pathophysiology, Diagnosis, and Management. Malden, MA: Blackwell Scientific; 1998.

10. PubMed Overview. Available at: https://pubmed.ncbi.nlm.nih.gov/about/.

11. Freedman-Cass DA, Fischer T, Alpert AB, et al. The Value and Process of Inclusion: Using Sensitive, Respectful, and Inclusive Language and Images in NCCN Content. J Natl Compr Canc Netw 2023;21:434–441. Available at: https://www.ncbi.nlm.nih.gov/pubmed/37156485.

12. Mentzel T, Pedeutour F, Lazar A, Coindre JM, eds. Dermatofibrosarcoma Protuberans in WHO Classification of Tumors of Soft Tissue and Bone. In: Fletcher CD, Bridge JA, Hogendoorn PCW, Mertens F, eds (ed 4): IARC Press; 2013.

13. Connective Tissue Tumors. In: Calonje E, Brenn T, Lazar A, McKee PH, eds. McKee's Pathology of the Skin with Clinical Correlations (ed 4): Elsevier Saunders; 2012:1630–1635.

14. Abenoza P, Lillemoe T. CD34 and factor XIIIa in the differential diagnosis of dermatofibroma and dermatofibrosarcoma protuberans. Am J Dermatopathol 1993;15:429–434. Available at: https://www.ncbi.nlm.nih.gov/pubmed/7694515.

15. Aiba S, Tabata N, Ishii H, et al. Dermatofibrosarcoma protuberans is a unique fibrohistiocytic tumour expressing CD34. Br J Dermatol 1992;127:79–84. Available at: https://www.ncbi.nlm.nih.gov/pubmed/1382538.

16. Kutzner H. Expression of the human progenitor cell antigen CD34 (HPCA-1) distinguishes dermatofibrosarcoma protuberans from fibrous histiocytoma in formalin-fixed, paraffin-embedded tissue. J Am Acad Dermatol 1993;28:613–617. Available at: https://www.ncbi.nlm.nih.gov/pubmed/7681857.

17. Goldblum JR, Tuthill RJ. CD34 and factor-XIIIa immunoreactivity in dermatofibrosarcoma protuberans and dermatofibroma. Am J

Version 2.2026 © 2025 National Comprehensive Cancer Network© (NCCN©), All rights reserved. NCCN Guidelines® and this illustration may not be reproduced in any form without the express written permission of NCCN.

PLEASE NOTE that use of this NCCN Content is governed by the End-User License Agreement, and you MAY NOT distribute this Content or use it with any artificial intelligence model or tool.
Printed by Máximo López Chenlo on 5/4/2026 6:18:17 PM. Copyright © 2026 National Comprehensive Cancer Network, Inc. All Rights Reserved.

Dermatopathol 1997;19:147–153. Available at: https://www.ncbi.nlm.nih.gov/pubmed/9129699.

18. Sellheyer K, Nelson P, Krahl D. Dermatofibrosarcoma protuberans: a tumour of nestin-positive cutaneous mesenchymal stem cells? Br J Dermatol 2009;161:1317–1322. Available at: https://www.ncbi.nlm.nih.gov/pubmed/19659472.

19. Cribier B, Noacco G, Peltre B, Grosshans E. Stromelysin 3 expression: a useful marker for the differential diagnosis dermatofibroma versus dermatofibrosarcoma protuberans. J Am Acad Dermatol 2002;46:408–413. Available at: https://www.ncbi.nlm.nih.gov/pubmed/11862177.

20. Lisovsky M, Hoang MP, Dresser KA, et al. Apolipoprotein D in CD34-positive and CD34-negative cutaneous neoplasms: a useful marker in differentiating superficial acral fibromyxoma from dermatofibrosarcoma protuberans. Mod Pathol 2008;21:31–38. Available at: https://www.ncbi.nlm.nih.gov/pubmed/17885669.

21. Yan X, Takahara M, Xie L, et al. Cathepsin K expression: a useful marker for the differential diagnosis of dermatofibroma and dermatofibrosarcoma protuberans. Histopathology 2010;57:486–488. Available at: https://www.ncbi.nlm.nih.gov/pubmed/20727023.

22. Buck DW, 2nd, Kim JY, Alam M, et al. Multidisciplinary approach to the management of dermatofibrosarcoma protuberans. J Am Acad Dermatol 2012;67:861–866. Available at: https://www.ncbi.nlm.nih.gov/pubmed/22387033.

23. Chappell AG, Doe SC, Worley B, et al. Multidisciplinary surgical treatment approach for dermatofibrosarcoma protuberans: an update. Arch Dermatol Res 2021;313:367–372. Available at: https://www.ncbi.nlm.nih.gov/pubmed/32770258.

24. Curtis KK, Fakult NJ, Strunck JL, et al. Establishing Consensus for Mohs Micrographic Surgical Techniques in the Treatment of Melanoma in Situ for Future Clinical Trials: A Modified Delphi Study. J Natl Compr Canc Netw 2024:1–6. Available at: https://www.ncbi.nlm.nih.gov/pubmed/39079545.

25. Connelly JH, Evans HL. Dermatofibrosarcoma protuberans. A clinicopathologic review with emphasis on fibrosarcomatous areas. Am J Surg Pathol 1992;16:921–925. Available at: https://www.ncbi.nlm.nih.gov/pubmed/1415902.

26. Szollosi Z, Nemes Z. Transformed dermatofibrosarcoma protuberans: a clinicopathological study of eight cases. J Clin Pathol 2005;58:751–756. Available at: https://www.ncbi.nlm.nih.gov/pubmed/15976346.

27. Mentzel T, Beham A, Katenkamp D, et al. Fibrosarcomatous ("high-grade") dermatofibrosarcoma protuberans: clinicopathologic and immunohistochemical study of a series of 41 cases with emphasis on prognostic significance. Am J Surg Pathol 1998;22:576–587. Available at: https://www.ncbi.nlm.nih.gov/pubmed/9591728.

28. Bowne WB, Antonescu CR, Leung DH, et al. Dermatofibrosarcoma protuberans: A clinicopathologic analysis of patients treated and followed at a single institution. Cancer 2000;88:2711–2720. Available at: https://www.ncbi.nlm.nih.gov/pubmed/10870053.

29. Abbott JJ, Oliveira AM, Nascimento AG. The prognostic significance of fibrosarcomatous transformation in dermatofibrosarcoma protuberans. Am J Surg Pathol 2006;30:436–443. Available at: https://www.ncbi.nlm.nih.gov/pubmed/16625088.

30. Ding J, Hashimoto H, Enjoji M. Dermatofibrosarcoma protuberans with fibrosarcomatous areas. A clinicopathologic study of nine cases and a comparison with allied tumors. Cancer 1989;64:721–729. Available at: https://www.ncbi.nlm.nih.gov/pubmed/2545326.

31. Hoesly PM, Lowe GC, Lohse CM, et al. Prognostic impact of fibrosarcomatous transformation in dermatofibrosarcoma protuberans: a cohort study. J Am Acad Dermatol 2015;72:419–425. Available at: https://www.ncbi.nlm.nih.gov/pubmed/25582537.

32. Lyu A, Wang Q. Dermatofibrosarcoma protuberans: A clinical analysis. Oncol Lett 2018;16:1855–1862. Available at: https://www.ncbi.nlm.nih.gov/pubmed/30008876.

33. Erdem O, Wyatt AJ, Lin E, et al. Dermatofibrosarcoma protuberans treated with wide local excision and followed at a cancer

Version 2.2026 © 2025 National Comprehensive Cancer Network© (NCCN©), All rights reserved. NCCN Guidelines® and this illustration may not be reproduced in any form without the express written permission of NCCN.

PLEASE NOTE that use of this NCCN Content is governed by the End-User License Agreement, and you MAY NOT distribute this Content or use it with any artificial intelligence model or tool.
Printed by Máximo López Chenlo on 5/4/2026 6:18:17 PM. Copyright © 2026 National Comprehensive Cancer Network, Inc. All Rights Reserved.

hospital: prognostic significance of clinicopathologic variables. Am J Dermatopathol 2012;34:24–34. Available at: https://www.ncbi.nlm.nih.gov/pubmed/21785324.

34. Jing C, Zhang H, Zhang X, Yu S. Dermatofibrosarcoma Protuberans: A Clinicopathologic and Therapeutic Analysis of 254 Cases at a Single Institution. Dermatol Surg 2021;47:e26–e30. Available at: https://www.ncbi.nlm.nih.gov/pubmed/32769521.

35. Li Y, Wang C, Xiang B, et al. Clinical Features, Pathological Findings and Treatment of Recurrent Dermatofibrosarcoma Protuberans. J Cancer 2017;8:1319–1323. Available at: https://www.ncbi.nlm.nih.gov/pubmed/28607608.

36. Goldblum JR, Reith JD, Weiss SW. Sarcomas arising in dermatofibrosarcoma protuberans: a reappraisal of biologic behavior in eighteen cases treated by wide local excision with extended clinical follow up. Am J Surg Pathol 2000;24:1125–1130. Available at: https://www.ncbi.nlm.nih.gov/pubmed/10935653.

37. Castle KO, Guadagnolo BA, Tsai CJ, et al. Dermatofibrosarcoma protuberans: long-term outcomes of 53 patients treated with conservative surgery and radiation therapy. Int J Radiat Oncol Biol Phys 2013;86:585–590. Available at: https://www.ncbi.nlm.nih.gov/pubmed/23628134.

38. Liang CA, Jambusaria-Pahlajani A, Karia PS, et al. A systematic review of outcome data for dermatofibrosarcoma protuberans with and without fibrosarcomatous change. J Am Acad Dermatol 2014;71:781–786. Available at: https://www.ncbi.nlm.nih.gov/pubmed/24755121.

39. Cai H, Wang Y, Wu J, Shi Y. Dermatofibrosarcoma protuberans: clinical diagnoses and treatment results of 260 cases in China. J Surg Oncol 2012;105:142–148. Available at: https://www.ncbi.nlm.nih.gov/pubmed/21815146.

40. Ugurel S, Mentzel T, Utikal J, et al. Neoadjuvant imatinib in advanced primary or locally recurrent dermatofibrosarcoma protuberans: a multicenter phase II DeCOG trial with long-term follow-up. Clin Cancer Res 2014;20:499–510. Available at: https://www.ncbi.nlm.nih.gov/pubmed/24173542.

41. Zhou X, Sun D, Liu Y, et al. Dermatofibrosarcoma protuberans: our 10-year experience on 80 patients. J Dermatolog Treat 2020;31:554–558. Available at: https://www.ncbi.nlm.nih.gov/pubmed/31116621.

42. Kimmel Z, Ratner D, Kim JY, et al. Peripheral excision margins for dermatofibrosarcoma protuberans: a meta-analysis of spatial data. Ann Surg Oncol 2007;14:2113–2120. Available at: https://www.ncbi.nlm.nih.gov/pubmed/17468914.

43. Chen Y, Jiang G. Association between surgical excision margins and outcomes in patients with dermatofibrosarcoma protuberans: A meta-analysis. Dermatol Ther 2021;34:e14954. Available at: https://www.ncbi.nlm.nih.gov/pubmed/33835635.

44. Gloster HM, Jr., Harris KR, Roenigk RK. A comparison between Mohs micrographic surgery and wide surgical excision for the treatment of dermatofibrosarcoma protuberans. J Am Acad Dermatol 1996;35:82–87. Available at: https://www.ncbi.nlm.nih.gov/pubmed/8682970.

45. DuBay D, Cimmino V, Lowe L, et al. Low recurrence rate after surgery for dermatofibrosarcoma protuberans: a multidisciplinary approach from a single institution. Cancer 2004;100:1008–1016. Available at: https://www.ncbi.nlm.nih.gov/pubmed/14983497.

46. Meguerditchian AN, Wang J, Lema B, et al. Wide excision or Mohs micrographic surgery for the treatment of primary dermatofibrosarcoma protuberans. Am J Clin Oncol 2010;33:300–303. Available at: https://www.ncbi.nlm.nih.gov/pubmed/19858696.

47. Foroozan M, Sei JF, Amini M, et al. Efficacy of Mohs micrographic surgery for the treatment of dermatofibrosarcoma protuberans: systematic review. Arch Dermatol 2012;148:1055–1063. Available at: https://www.ncbi.nlm.nih.gov/pubmed/22986859.

48. Bogucki B, Neuhaus I, Hurst EA. Dermatofibrosarcoma protuberans: a review of the literature. Dermatol Surg 2012;38:537–551. Available at: https://www.ncbi.nlm.nih.gov/pubmed/22288484.

49. Paradisi A, Abeni D, Rusciani A, et al. Dermatofibrosarcoma protuberans: wide local excision vs. Mohs micrographic surgery.

Version 2.2026 © 2025 National Comprehensive Cancer Network© (NCCN©), All rights reserved. NCCN Guidelines® and this illustration may not be reproduced in any form without the express written permission of NCCN.

PLEASE NOTE that use of this NCCN Content is governed by the End-User License Agreement, and you MAY NOT distribute this Content or use it with any artificial intelligence model or tool.
Printed by Máximo López Chenlo on 5/4/2026 6:18:17 PM. Copyright © 2026 National Comprehensive Cancer Network, Inc. All Rights Reserved.

Cancer Treat Rev 2008;34:728–736. Available at: https://www.ncbi.nlm.nih.gov/pubmed/18684568.

50. Lowe GC, Onajin O, Baum CL, et al. A comparison of mohs micrographic surgery and wide local excision for treatment of dermatofibrosarcoma protuberans with long-term follow-up: The mayo clinic experience. Dermatol Surg 2017;43:98–106. Available at: https://www.ncbi.nlm.nih.gov/pubmed/27749444.

51. Veronese F, Boggio P, Tiberio R, et al. Wide local excision vs. Mohs Tubingen technique in the treatment of dermatofibrosarcoma protuberans: a two-centre retrospective study and literature review. J Eur Acad Dermatol Venereol 2017;31:2069–2076. Available at: https://www.ncbi.nlm.nih.gov/pubmed/28573714.

52. Malan M, Xuejingzi W, Quan SJ. The efficacy of Mohs micrographic surgery over the traditional wide local excision surgery in the cure of dermatofibrosarcoma protuberans. Pan Afr Med J 2019;33:297. Available at: https://www.ncbi.nlm.nih.gov/pubmed/31692830.

53. Durack A, Gran S, Gardiner MD, et al. A 10-year review of surgical management of dermatofibrosarcoma protuberans. Br J Dermatol 2021;184:731–739. Available at: https://www.ncbi.nlm.nih.gov/pubmed/32599647.

54. Farma JM, Ammori JB, Zager JS, et al. Dermatofibrosarcoma protuberans: how wide should we resect? Ann Surg Oncol 2010;17:2112–2118. Available at: https://www.ncbi.nlm.nih.gov/pubmed/20354798.

55. Snow H, Davies E, Strauss DC, et al. Conservative re-excision is a safe and simple alternative to radical resection in revision surgery for dermatofibrosarcoma protuberans. Ann Surg Oncol 2020;27:919–923. Available at: https://www.ncbi.nlm.nih.gov/pubmed/31664620.

56. Harati K, Lange K, Goertz O, et al. A single-institutional review of 68 patients with dermatofibrosarcoma protuberans: wide re-excision after inadequate previous surgery results in a high rate of local control. World J Surg Oncol 2017;15:5. Available at: https://www.ncbi.nlm.nih.gov/pubmed/28056985.

57. Suit H, Spiro I, Mankin HJ, et al. Radiation in management of patients with dermatofibrosarcoma protuberans. J Clin Oncol 1996;14:2365–2369. Available at: https://www.ncbi.nlm.nih.gov/pubmed/8708729.

58. Uysal B, Sager O, Gamsiz H, et al. Evaluation of the role of radiotherapy in the management of dermatofibrosarcoma protuberans. J BUON 2013;18:268–273. Available at: https://www.ncbi.nlm.nih.gov/pubmed/23613415.

59. Hamid R, Hafeez A, Darzi MA, et al. Outcome of wide local excision in dermatofibrosarcoma protuberans and use of radiotherapy for margin-positive disease. Indian Dermatol Online J 2013;4:93–96. Available at: https://www.ncbi.nlm.nih.gov/pubmed/23741663.

60. Ballo MT, Zagars GK, Pisters P, Pollack A. The role of radiation therapy in the management of dermatofibrosarcoma protuberans. Int J Radiat Oncol Biol Phys 1998;40:823–827. Available at: https://www.ncbi.nlm.nih.gov/pubmed/9531366.

61. Dagan R, Morris CG, Zlotecki RA, et al. Radiotherapy in the treatment of dermatofibrosarcoma protuberans. Am J Clin Oncol 2005;28:537–539. Available at: https://www.ncbi.nlm.nih.gov/pubmed/16317260.

62. Sun LM, Wang CJ, Huang CC, et al. Dermatofibrosarcoma protuberans: treatment results of 35 cases. Radiother Oncol 2000;57:175–181. Available at: https://www.ncbi.nlm.nih.gov/pubmed/11054521.

63. Williams N, Morris CG, Kirwan JM, et al. Radiotherapy for dermatofibrosarcoma protuberans. Am J Clin Oncol 2014;37:430–432. Available at: https://www.ncbi.nlm.nih.gov/pubmed/23388563.

64. Haas RL, Keus RB, Loftus BM, et al. The role of radiotherapy in the local management of dermatofibrosarcoma protuberans. Soft Tissue Tumours Working Group. Eur J Cancer 1997;33:1055–1060. Available at: https://www.ncbi.nlm.nih.gov/pubmed/9376187.

65. Chen YT, Tu WT, Lee WR, Huang YC. The efficacy of adjuvant radiotherapy in dermatofibrosarcoma protuberans: a systemic review

Version 2.2026 © 2025 National Comprehensive Cancer Network© (NCCN©), All rights reserved. NCCN Guidelines® and this illustration may not be reproduced in any form without the express written permission of NCCN.

PLEASE NOTE that use of this NCCN Content is governed by the End-User License Agreement, and you MAY NOT distribute this Content or use it with any artificial intelligence model or tool.
Printed by Máximo López Chenlo on 5/4/2026 6:18:17 PM. Copyright © 2026 National Comprehensive Cancer Network, Inc. All Rights Reserved.

and meta-analysis. J Eur Acad Dermatol Venereol 2016;30:1107–1114. Available at: https://www.ncbi.nlm.nih.gov/pubmed/26879523.

66. Takahira T, Oda Y, Tamiya S, et al. Detection of COL1A1-PDGFB fusion transcripts and PDGFB/PDGFRB mRNA expression in dermatofibrosarcoma protuberans. Mod Pathol 2007;20:668–675. Available at: https://www.ncbi.nlm.nih.gov/pubmed/17431412.

67. Patel KU, Szabo SS, Hernandez VS, et al. Dermatofibrosarcoma protuberans COL1A1-PDGFB fusion is identified in virtually all dermatofibrosarcoma protuberans cases when investigated by newly developed multiplex reverse transcription polymerase chain reaction and fluorescence in situ hybridization assays. Hum Pathol 2008;39:184–193. Available at: https://www.ncbi.nlm.nih.gov/pubmed/17950782.

68. Simon MP, Pedeutour F, Sirvent N, et al. Deregulation of the platelet-derived growth factor B-chain gene via fusion with collagen gene COL1A1 in dermatofibrosarcoma protuberans and giant-cell fibroblastoma. Nat Genet 1997;15:95–98. Available at: https://www.ncbi.nlm.nih.gov/pubmed/8988177.

69. Rutkowski P, Van Glabbeke M, Rankin CJ, et al. Imatinib mesylate in advanced dermatofibrosarcoma protuberans: pooled analysis of two phase II clinical trials. J Clin Oncol 2010;28:1772–1779. Available at: https://www.ncbi.nlm.nih.gov/pubmed/20194851.

70. Navarrete-Dechent C, Mori S, Barker CA, et al. Imatinib treatment for locally advanced or metastatic dermatofibrosarcoma protuberans: A systematic review. JAMA Dermatol 2019;155:361–369. Available at: https://www.ncbi.nlm.nih.gov/pubmed/30601909.

71. Kerob D, Porcher R, Verola O, et al. Imatinib mesylate as a preoperative therapy in dermatofibrosarcoma: results of a multicenter phase II study on 25 patients. Clin Cancer Res 2010;16:3288–3295. Available at: https://www.ncbi.nlm.nih.gov/pubmed/20439456.

72. McArthur GA, Demetri GD, van Oosterom A, et al. Molecular and clinical analysis of locally advanced dermatofibrosarcoma protuberans treated with imatinib: Imatinib Target Exploration Consortium Study B2225. J Clin Oncol 2005;23:866–873. Available at: https://www.ncbi.nlm.nih.gov/pubmed/15681532.

73. Rutkowski P, Debiec-Rychter M, Nowecki Z, et al. Treatment of advanced dermatofibrosarcoma protuberans with imatinib mesylate with or without surgical resection. J Eur Acad Dermatol Venereol 2011;25:264–270. Available at: https://www.ncbi.nlm.nih.gov/pubmed/20569296.

Version 2.2026 © 2025 National Comprehensive Cancer Network© (NCCN©), All rights reserved. NCCN Guidelines® and this illustration may not be reproduced in any form without the express written permission of NCCN.